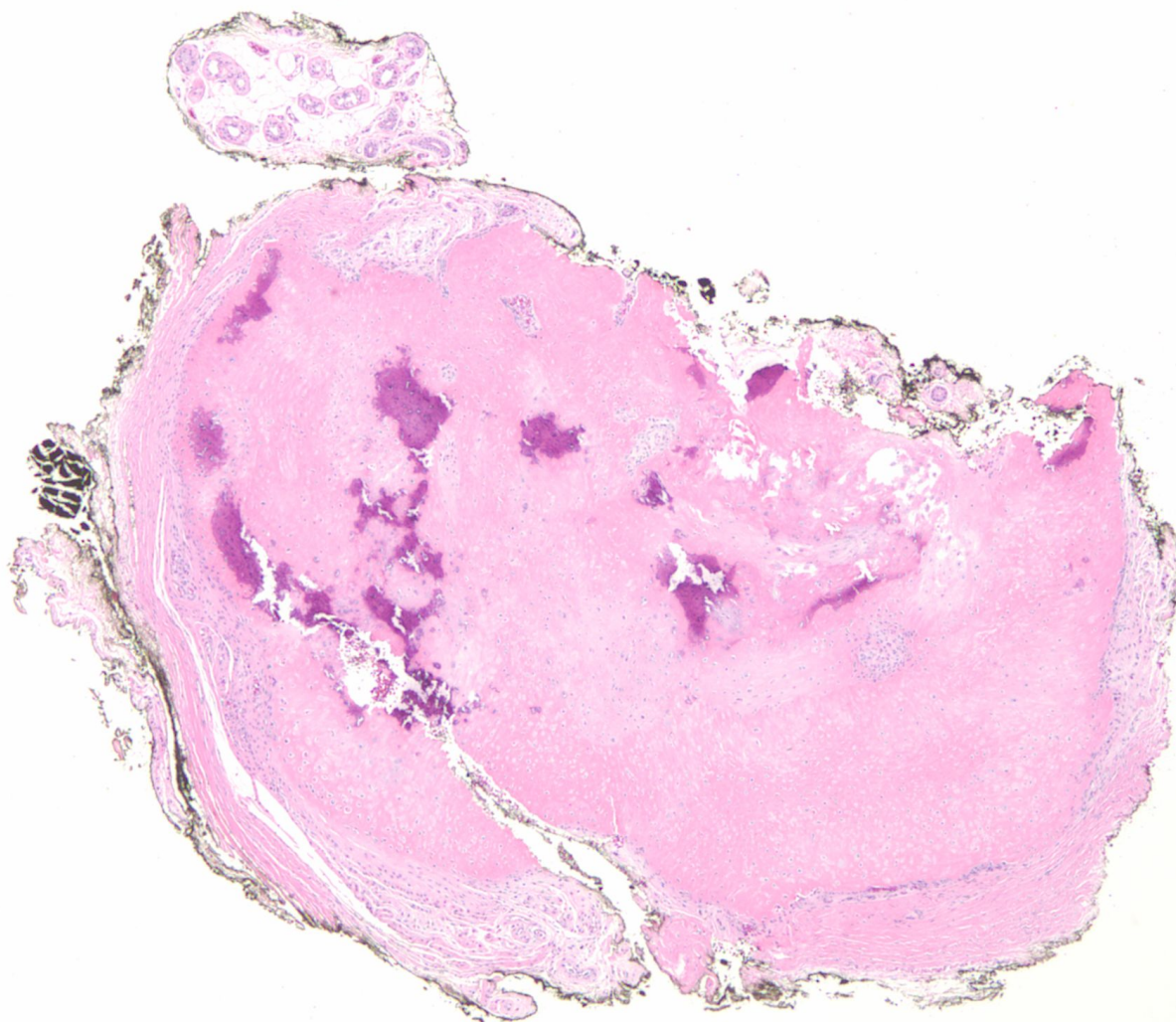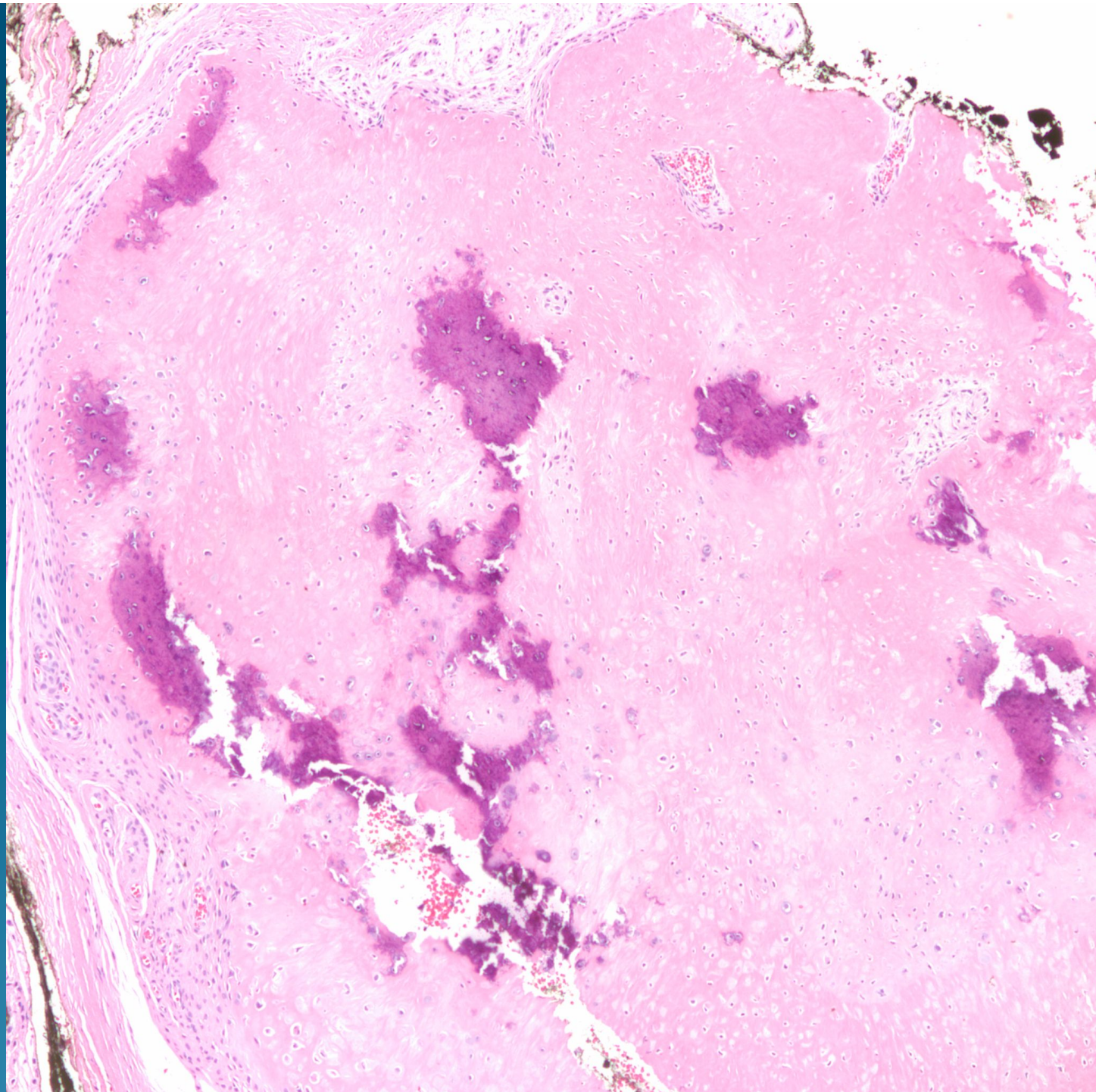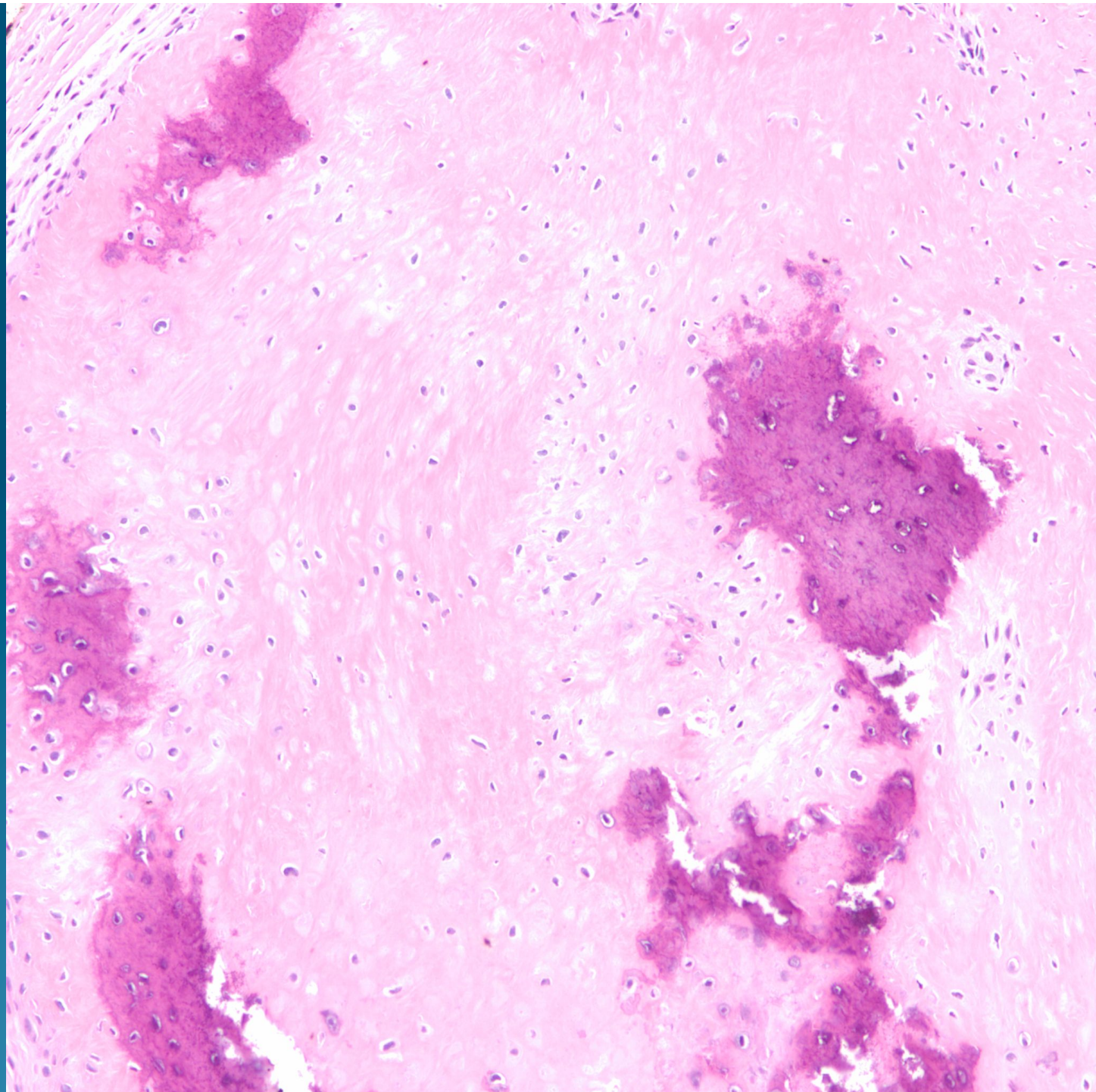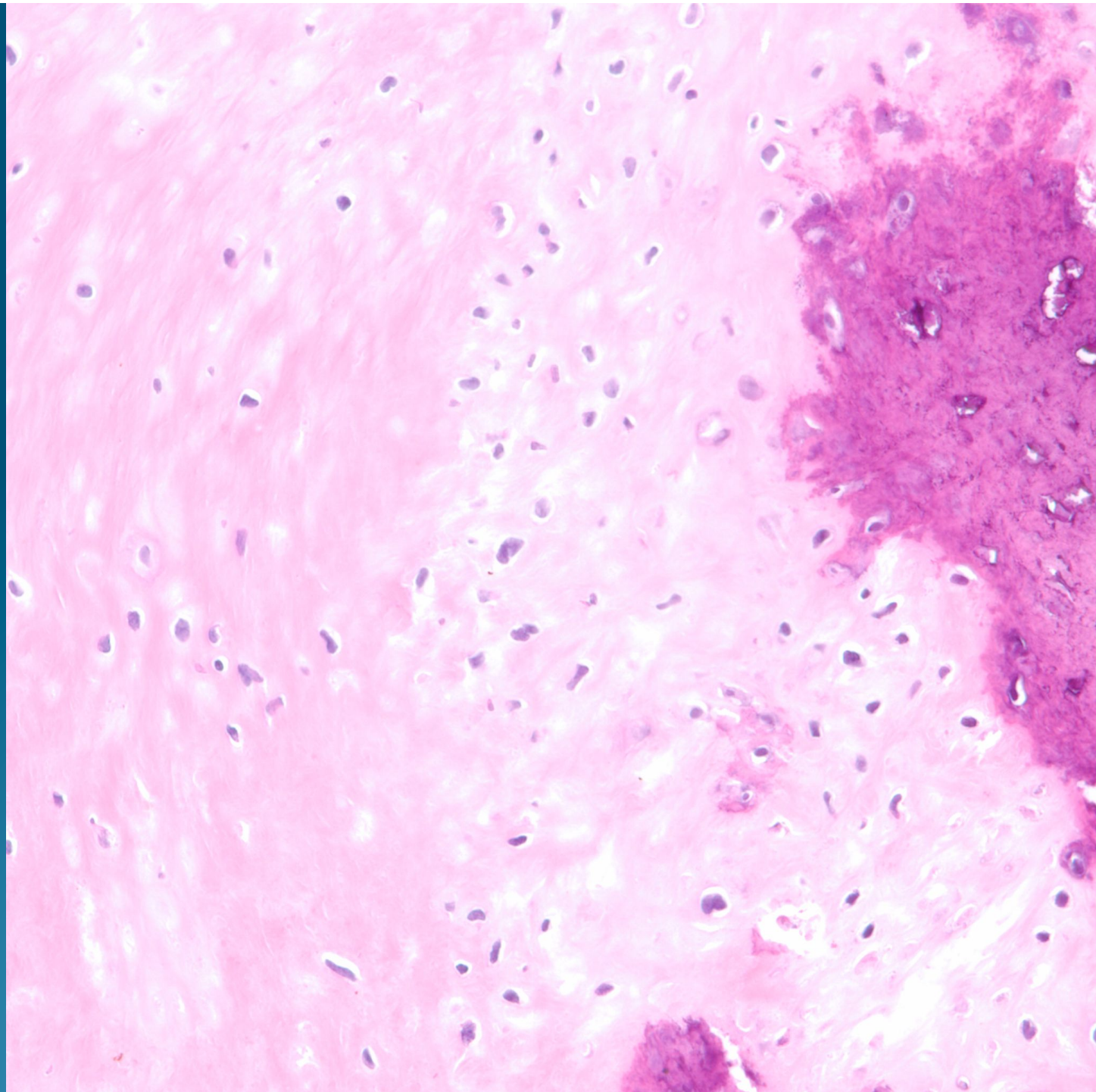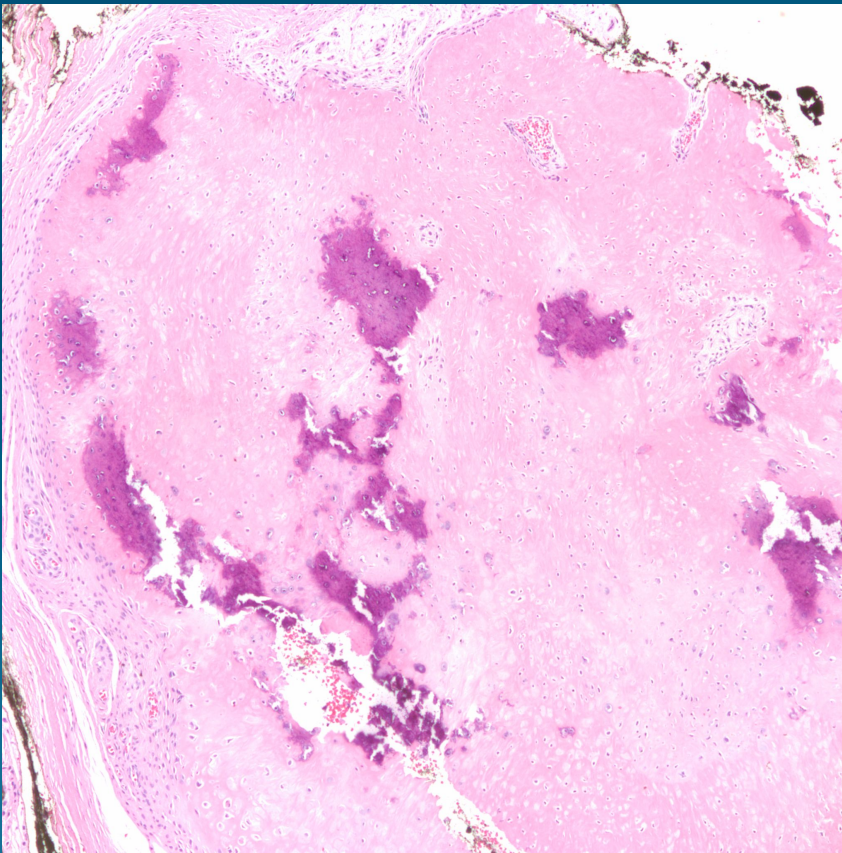


What is the best diagnosis?

- A. Chondrodermatitis nodularis helices
- B. Osteoid osteoma
- C. Chondrosarcoma
- D. Ossifying fibromyxoid tumor
- E. Osteoma cutis

Osteoma Cutis

Pearls



- Mature bone with varying degrees of ossification and calcification
- Histologically benign and usually circumscribed
- May see antecedent lesion such as epidermal cyst or hemangioma